

Abdominal Aortic Tourniquet Controls Junctional Hemorrhage From a Gunshot Wound of the Axilla

John Croushorn, MD, FACEP; Jim McLester, MD;
Gregory Thomas, MD, FACS, FACCP; Scott R. McCord, MD

ABSTRACT

Junctional hemorrhage, bleeding from the areas at the junction of the trunk and its appendages, is a difficult problem in trauma. These areas are not amenable to regular tourniquets as they cannot fit to give circumferential pressure around the extremity. Junctional arterial injuries can rapidly lead to death by exsanguination, and out-of-hospital control of junctional bleeding can be lifesaving. The present case report describes an off-label use of the Abdominal Aortic Tourniquet™ in the axilla and demonstrates its safety and effectiveness of stopping hemorrhage from a challenging wound. To our knowledge, the present report is the first human use of a junctional tourniquet to control an upper extremity junctional hemorrhage.

KEYWORDS: *Abdominal Aortic Tourniquet™, AAT, hemorrhage, amputations*

Introduction

The U.S. military has identified junctional hemorrhage control as an important capability gap in military medicine.¹ One recent review of battle casualties found that 21% of casualties who died of wounds had junctional bleeding possibly amenable to a truncal tourniquet.² The Abdominal Aortic Tourniquet™ (AAT; Compression Works LLC; compressionworks.net) (NSN 6515-01-616-4999) was applied to a casualty in Afghanistan previously in 2013.^{3,4} The AAT rapidly stopped the bleeding in the Afghan case and AAT use freed the hands of medical providers to perform other lifesaving prehospital interventions on that casualty with multiple life-threatening injuries.

The utility of a device that safely stops all blood flow distal to point of application is of great use. The idea that a truncal tourniquet already indicated for groin bleeding could be used for the upper extremity as well has tremendous value added for both military and civilian trauma.

The present case report describes an off-label use of the AAT in the axilla and demonstrates its safety and effectiveness of stopping hemorrhage from a challenging wound. To our knowledge, the present report is the first human use of a junctional tourniquet to control an upper extremity junctional hemorrhage.

Case Report

A 41-year-old man was driven up to the main entrance of the emergency department. The patient had sustained a gunshot wound to the left upper arm that traversed his left axilla and entered his left chest (Figure 1). A large amount of blood was noted in the vehicle. The patient was unresponsive. He was transferred to a resuscitation room, and direct manual pressure was applied to the left axillary region to control the hemorrhage.

The diaphoretic patient was completely unresponsive. The primary emergency physician focused on hemorrhage control, and a partner focused on securing the airway, which was initially done with bag-valve-mask ventilation. Monitoring at that time showed a heart

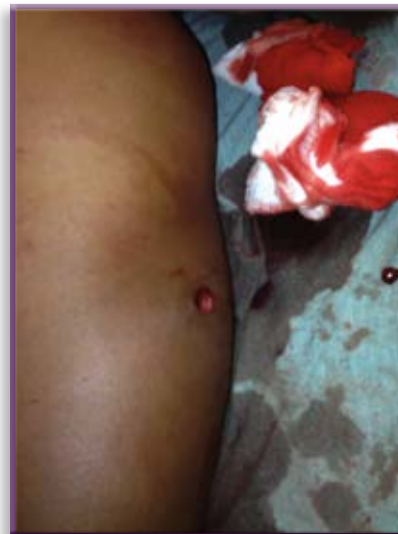

Figure 1 *The entrance wound is in the upper left arm over the proximal portion of the triceps muscle belly and distal to the margin of the deltoid muscle.*

rate of 130 beats/minute, but blood pressure was too low to be detected when measurement was attempted. A thready carotid pulse was noted. With tachycardia, unobtainable blood pressure, and unconscious state, the patient was in class IV hemorrhagic shock, so 4 units of emergent O-negative packed red blood cells (PRBCs) was requested and was at the bedside 13 minutes after the patient's arrival.

The AAT was applied by the primary emergency physician around the upper torso with the bladder against the upper chest wall just below two axillary wounds (Figure 2). The belt was secured around the opposite shoulder's deltoid muscle. The belt was tightened, the windlass was then tightened and secured, and the bladder was inflated until the manometer showed green, indicating 250mmHg pressure. The nurse holding pressure on the two axillary wounds was asked to remove her hands from the wounds, and no blood loss occurred (Figure 3). An intraosseous (IO) line was inserted in the patient's right proximal tibia. The IO line was used to infuse blood products and medications to complete the rapid sequence intubation (RSI) for control of the patient's

Figure 2 Emergency department use of Abdominal Aortic Tourniquet (AAT) for an axillary hemorrhage. The pressure gauge has its green indicator visible (arrow) for 250mmHg pressure within the bladder of the AAT. The image is of the moment between initial AAT use and the freeing up of the nurse's hands by removal of bimanual compression of the wounds (bottom right).

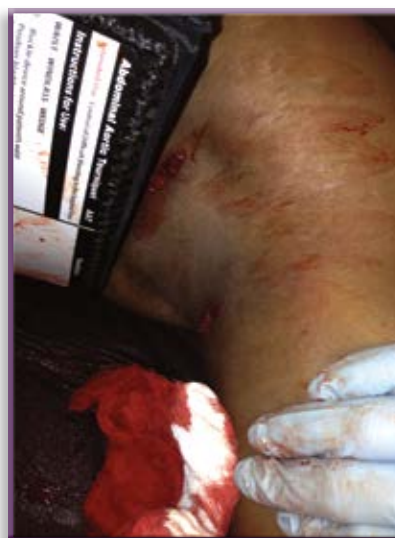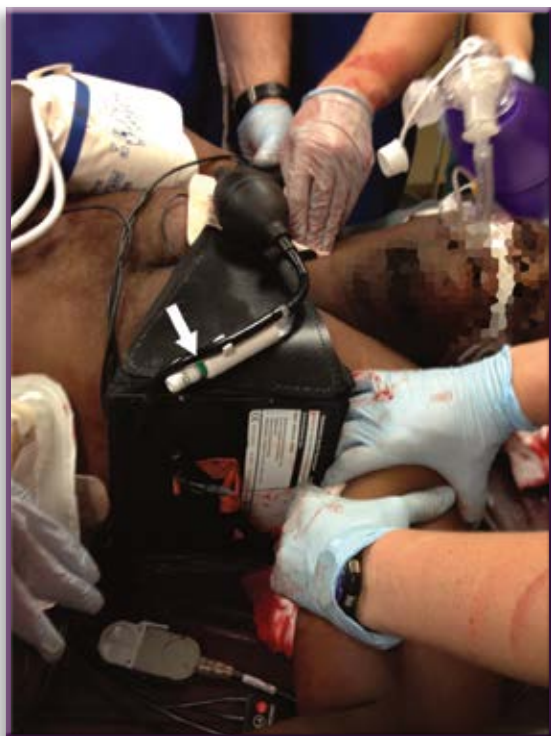


Figure 3 Two axillary wounds were spurting pulsatile blood until the AAT was applied. At the bottom, the right hand is assessing the distal pulse in the brachial artery.

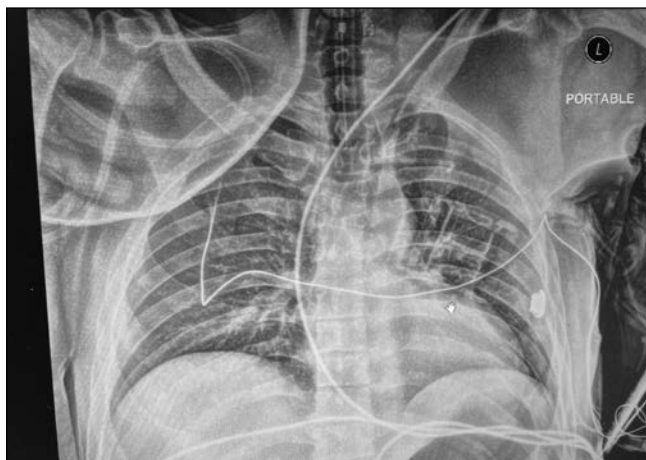
airway. The first unit of PRBCs was started as the RSI medications were given.

The airway was controlled with direct laryngoscopy and endotracheal tube (ETT) intubation with 100mg of succinylcholine. Auscultation detected decreased breath sounds in the left chest even after tube repositioning, and it was unclear if decreased sounds were from pneumothorax or AAT use. A 14-gauge angiocath was inserted into the upper left chest.

A portable chest radiograph revealed that the lung was inflated, the ETT was in good position, and a bullet appeared to reside in the left chest wall outside the ribs (Figure 4). The radiograph also showed that the pneumatic wedge of the AAT's bladder was displacing significant soft tissue toward the proximal clavicle. The patient was easy to ventilate with the bag. The second and third units of PRBCs were given. After the third unit of PRBCs, the patient became responsive. He moved his right arm and tried to sit up in the bed; in doing so, he displaced the AAT belt. During this time, hemorrhage control was lost temporarily. Direct manual pressure was once again applied to the axillary wounds. He was administered 50mg rocuronium, and the AAT was replaced and tightened and the wounds were evaluated for hemostasis. A fourth unit of PRBCs was then started.

At this time, the cardiothoracic surgeon was bedside. The patient was too unstable to transfer to a Level I trauma center and required resuscitative surgery for hemorrhage control. The patient was transferred from the emergency department to the operating room at 17:19 hours. Throughout transport and movement to the operating table the AAT remained inflated and no blood loss was noted from the axillary wounds.

Figure 4 The chest radiograph shows the AAT placed in the left axilla (“L” indicates the casualty’s left side). The air-filled wedge of the AAT compresses the axilla below the word “portable.” The AAT compresses and displaces soft tissue in the left axilla toward the clavicle; the humerus is also pushed away into abduction.



The patient was positioned and prepared for surgery, and a femoral arterial line was started. The AAT was deflated and removed. Without significant manual pressure held on the two axillary wounds, bright red, pulsatile blood spurting from the wounds. A left infraclavicular incision was made, and the pectoralis major muscle was identified. The axilla was entered just medial to the pectoralis minor muscle, and the subclavian vein was identified with the basilic vein entering into it. The axillary artery was identified and circumferentially dissected. It was encircled twice with a vascular tape. Once the tape was tightened, manual compression was released from the wounds, and hemorrhage control was seen. A 36-French chest tube was inserted into the left pleural space. No blood egressed, indicating there was no hemothorax.

The vascular surgeon then dealt with the vascular injury. An incision connecting the two axillary wounds was made to open the axilla. A macerated and destroyed segment of the origin of the brachial artery was noted. The vessel loop around the axillary artery was loosened, and the bleeding onset confirmed the destroyed segment as being from the brachial artery, the continuation of the axillary artery. The brachial artery was dissected out distally. After debridement, mobilization, and reduction, the gap between the two ends of the disrupted brachial artery was approximately 6cm. An 8cm segment of saphenous vein was used to bridge the defect as a reversed autograft. One revision of the anastomosis was required before the Doppler signal from the patient’s left radial artery at the wrist confirmed pulsatile arterial flow was present distal to the vascular reconstruction. Estimated blood loss during surgery was 700 to 800ml. The patient

was transferred to the surgical intensive care unit with hemorrhage controlled and arterial blood flow restored to the affected extremity.

Although the AAT compressed the left thorax, ventilator inspiratory pressures were normal. By day 3, the patient was extubated, awake, moving his left hand, and following commands.

Lessons Learned

Slack removal is essential for optimal use, as with any tourniquet. Because we place the AAT upright routinely, the buckle ended up under the supine patient. To fully tighten the belt of the AAT, we had to perform several extra log rolls. The AAT can be upright with the text on the device label facing either up or down. Both orientations have equal efficacy, but in unilateral application in the axilla, groin, or neck on the left side of the body, placing the AAT upside down with the label text inverted allows the buckle to be on the anterior chest of the patient instead of behind the back. Upside-down use yields faster and easier strap tightening to remove all slack.

The AAT is

- A Food and Drug Administration–cleared device that is currently indicated for difficult inguinal bleeding on the battlefield, and approval for isolated groin, axillary, and neck applications are under way.
- Is the only junctional tourniquet with the CE mark if approval.
- Is the only junctional tourniquet reported with a successful axillary use.

Disclosures

Dr. Croushorn is one of the inventors of the Abdominal Aortic Tourniquet and the president of Compression Works LLC, which developed the device. The other authors have no disclosures.

References

1. Kragh JF Jr, Murphy C, Dubick MA, et al. New tourniquet device concepts for battlefield hemorrhage control. *Prehosp Combat Casualty Care*. 2011;38.
2. Eastridge BJ, Hardin M, Cantrell J, et al. Died of wounds on the battlefield: causation and implications for improving combat casualty care. *J Trauma Acute Care Surg*. 2011; 71:S4–S8.
3. Anonymous. Case report: Abdominal Aortic Tourniquet™ use in Afghanistan. *J Spec Oper Med*. 2013;3:1–2.
4. Croushorn J, Calloway D. Abdominal Aortic Tourniquet™ Commentary. *J Spec Oper Med*. 2013;13:3.

Dr. Croushorn has been involved in hemorrhage control research since 2005. He is a board-certified emergency physician who lives in Birmingham, AL. He was a former Command Surgeon, Task Force 185, OIF 2004.

Dr. McLester is a board-certified emergency physician who lives in Birmingham, AL.

Dr. Thomas has been a practicing cardiothoracic surgeon for 13 years, the last 10 in Birmingham AL. He is board-certified in both general and thoracic surgery. He completed his general

surgery training at the Detroit Medical Center and Detroit Receiving Hospital, and he trained as a fellow in cardiothoracic surgery at the Mayo Clinic in Rochester, MN.

Dr. McCord has been a practicing vascular surgeon for 18 years. He is board-certified in both general and vascular surgery. He completed his general surgery training and fellowship in vascular surgery at the University of Tennessee.